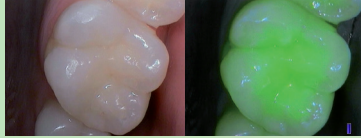

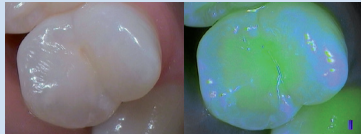
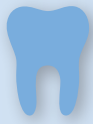## Diagnostic mode

## Treatment mode

HEALTHY TEETH

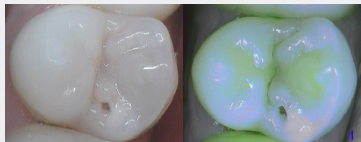


Healthy dentin



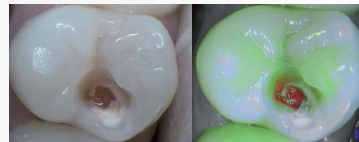Healthy and thick enamel appears in blue at the cusps. Healthy dentin is green

CARIOUS LESIONS

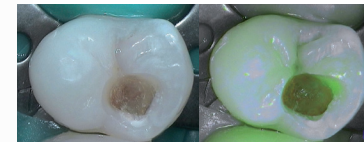


Lack of fluorescence shows the presence of an enamodental carious lesion (demineralization)

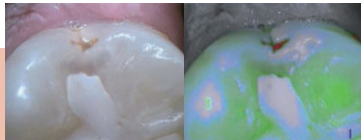
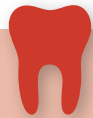### Cavity opening



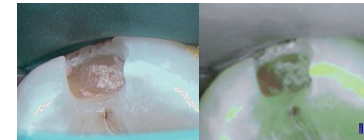
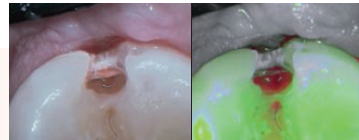
### End of the excavation



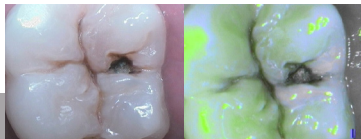The floor of the cavity is green: the active caries is completely removed



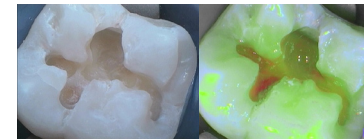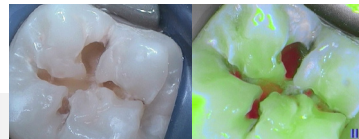
A red signal surrounded by a lack of fluorescence (demineralization) indicates the presence of an enamodental carious lesion



Presence of green-orange hard tissues at the bottom of the cavity: slow evolution of decay completely removed while keeping the healthy tertiary dentin



A black zone surrounded by a demineralization (lack of fluorescence) shows the presence of an enamodental carious lesion







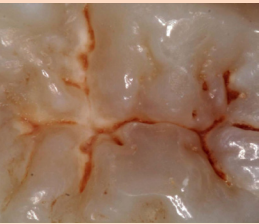

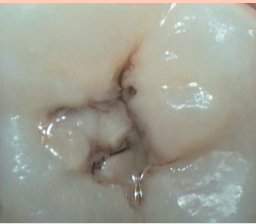
Presence of green-orange hard tissues at the bottom of the cavity: slow evolution of decay completely removed while keeping the healthy tertiary dentin

*From the article of Pr. Tassery, Head of the Preventive and Restorative Department, Marseilles Dental School, University AMU, LBN Montpellier I. Published in Minim. Interv. Dent. 2011 and in Clin. Oral. Invest. 2013*

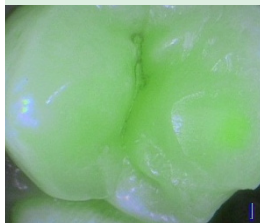




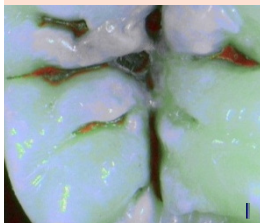
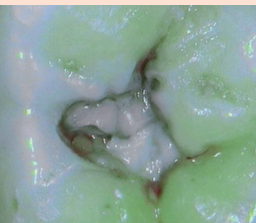
The medical device for dental care SOPROLIFE is of class IIa and manufactured by SOPRO notified body LNE/GMED. This medical device is not reimbursed by health insurance organizations. Read carefully the instructions on the labelling before use.

# SoproLife Caries Classification

ICDAS II  
Classification

SOUND	EARLY STAGE DECAY		ESTABLISHED DECAY		SEVERE DECAY	
CODE 0	CODE 1	CODE 2	CODE 3	CODE 4	CODE 5	CODE 6
						
Sound	First visual change in enamel	Distinct visual change in enamel	Localized enamel breakdown	Underlying dentin shadow	Distinct cavity with visible dentin	Extensive cavity with visible dentin

SOPRO LIFE  
Classification

						
No visible change in enamel	Thin red shimmer in the pits and fissure system, no red dots visible	In addition to red shimmer in pits and possibly coming up slopes darker red spots confined to the fissure are visible	Dark red extended areas confined to the fissures; slight beginning roughness possible	Dark red or orange areas wider than fissures; surface roughness occurs	Obvious openings with visible dentin	Wide areas of visible dentin



From the article of Pr. Rechmann, Director of the Clinical Sciences Research Group, Department of Preventive and Restorative Dental Sciences, School of Dentistry, University of California, San Francisco. Published in the JBO in April 2012  
From the article of Pr. Tassery, Head of the Preventive and Restorative Department, Marseilles Dental School, University AMU, LBN Montpellier I. Published in Minim. Interv. Dent. 2011 and in Clin. Oral. Invest. 2013